

Picibanil vs surgical excision lymphangioma

Author: Smolecule Technical Support Team. **Date:** February 2026

Compound Focus: Picibanil

CAS No.: 39325-01-4

Cat. No.: S607217

Get Quote

Treatment Modalities at a Glance

The table below summarizes the core characteristics of the two treatment options based on the gathered clinical studies.

Feature	Picibanil (OK-432) Sclerotherapy	Surgical Excision
Mechanism of Action	Induces a controlled inflammatory reaction, causing cyst wall adhesion and fibrosis [1] [2].	Physical removal of the lymphangioma tissue [3] [4].
Primary Indication	First-line for macrocytic and mixed-type lymphangiomas [1].	Used across all types; often preferred for microcystic lesions, symptomatic intra-abdominal lesions, or after sclerotherapy failure [3] [5] [6].
Efficacy & Recurrence	High efficacy: 86.4% excellent/good response (>50% regression) in one study [1].	Curative intent: Complete excision aims to prevent recurrence; recurrence rates are variable (e.g., 9.4% in one abdominal study) [3] [6].

Feature	Picibanil (OK-432) Sclerotherapy	Surgical Excision
Common Side Effects/Complications	Frequent but typically transient: swelling, redness, fever, and pain [1].	Standard surgical risks: infection, bleeding, nerve injury, and seroma formation [3] [4].
Key Advantages	Less invasive, avoids surgical scars, lower risk of nerve damage, preferred by patients/parents [1].	Provides definitive histopathological diagnosis, can be curative with complete resection [3] [6].
Key Limitations	Less effective for microcystic lesions; post-injection swelling can risk airway compromise in cervicofacial lesions [1] [2].	Risk of damage to vital structures; complete excision can be difficult; poorer cosmetic outcome [1] [3].
Technical Considerations	Ultrasound-guided intracavitary injection after cyst aspiration; often requires general anesthesia [1] [2].	Laparoscopic approach is safe and feasible for appropriate intra-abdominal cases [3]. Techniques like "quilting" sutures can reduce seroma risk [4].

Detailed Experimental Data and Protocols

For researchers, a deeper understanding of the experimental methodologies and specific outcomes is crucial.

Quantitative Efficacy Data

The following table consolidates key results from the clinical studies retrieved.

Study (Population)	Treatment	Key Efficacy Metrics	Key Safety Findings
--------------------	-----------	----------------------	---------------------

| **Retrospective Study (n=37; 30 children) [1] | Picibanil Sclerotherapy | • 86.4% (32/37) showed excellent/good response (>50% regression). • 8.1% (3/37) showed no response. | Most common side effects: swelling (89%), fever (81%), redness (81%), pain (73%). No serious side effects reported. | | **Retrospective Study (n=32; Adults, Intra-abdominal) [3] | Surgical Excision | • Recurrence rate: 9.4% (3/32). • Laparoscopic surgery was performed in 37.5% of cases. | - | | **Case Report (Breast Lymphangioma) [4] | Surgical Excision with Quilting | • No recurrence at follow-up. | Successful prevention of post-operative seroma. | | **Case Series (n=7; Superficial LM) [5] [7] | Bleomycin Sclerotherapy (Note: different sclerosant) | • Marked reduction in lesions after a median of 1 course. • No recurrence requiring retreatment. | No serious complications; transient vomiting (1 patient), temporary skin pigmentation (2 patients). |********

Detailed Experimental Protocols

To ensure reproducible results, here are the detailed methodologies for the two main procedures as described in the literature.

Picibanil (OK-432) Sclerotherapy Protocol [1] [2]

- **Patient Preparation & Diagnosis:** Diagnosis is confirmed via ultrasound or MRI to classify the lesion as macrocystic or mixed. Patients with microcystic lesions are typically excluded.
- **Procedure:** Performed under sterile conditions, often with general anesthesia, especially for children or complex locations.
 - Under **ultrasound guidance**, one or more cysts are punctured and the lymphatic fluid is aspirated as much as possible.
 - An equivalent volume of **OK-432 solution** (0.01 mg/mL in normal saline) is injected into the cavity. The total dose should not exceed 0.2 mg (20 mL of the prepared solution) in a single session [1].
- **Post-procedure Care:** Patients are typically observed as inpatients for 1-3 days to monitor for fever, swelling, and potential airway compromise in head and neck cases.

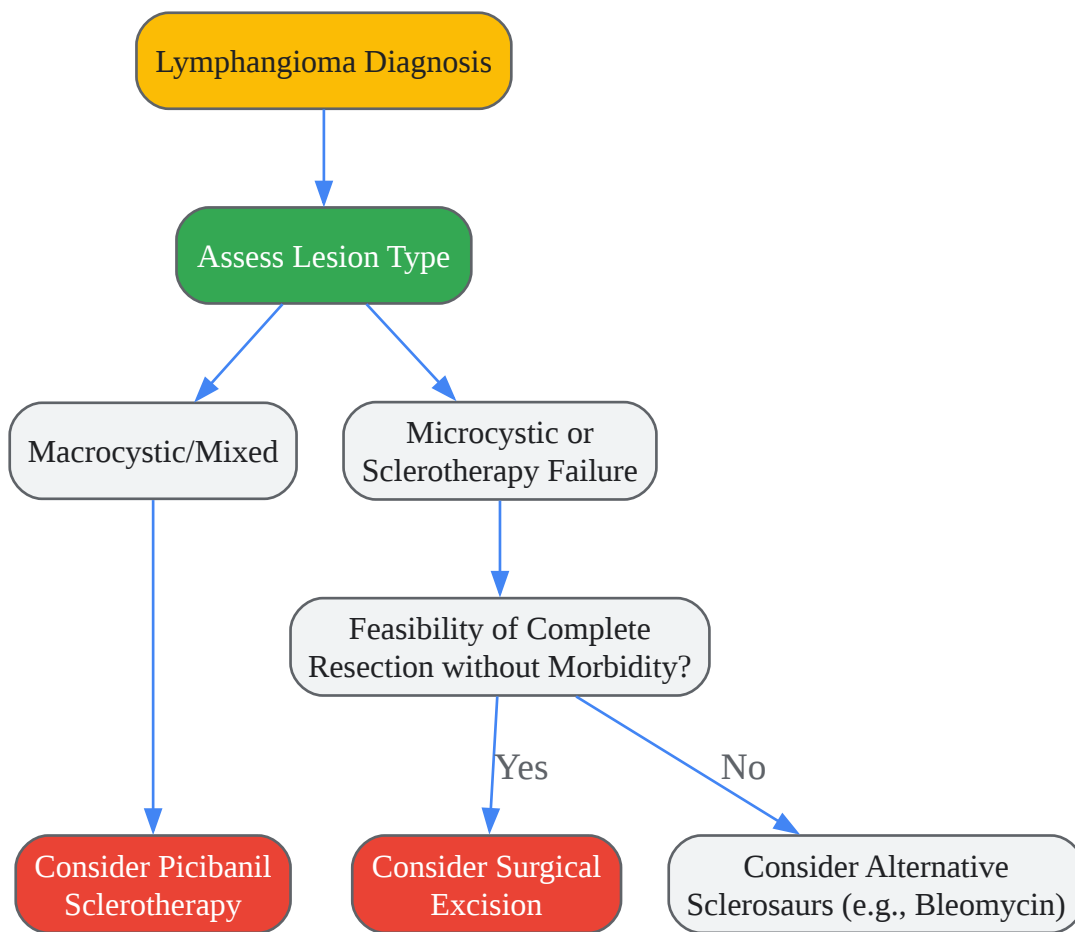
Surgical Excision Protocol for Intra-Abdominal Lymphangioma [3]

- **Pre-operative Workup:** Imaging with **CT or MRI** is essential to define the anatomical extent and relationship to vital structures.
- **Surgical Approach:** The choice between **open or laparoscopic** surgery is based on the lesion's size and location.
 - The goal is **complete cystectomy** without rupture to prevent recurrence.

- Dissection is meticulous to avoid damage to surrounding organs and vessels.
- **Intra-operative Adjuncts:** For large cavities post-excision (e.g., in the breast), a **quilting technique**—placing multiple sutures to obliterate dead space—can significantly reduce the risk of seroma formation [4].

Decision Workflow and Clinical Considerations

The following diagram illustrates the key decision-making process for choosing between these treatments, synthesized from the evidence in the search results.



[Click to download full resolution via product page](#)

The evidence shows a clear trend toward favoring sclerotherapy as a first-line treatment for suitable macrocystic lesions to avoid surgical morbidity. However, surgery remains a definitive and necessary option, especially with the advancement of laparoscopic techniques. For researchers, key development areas include

improving sclerotherapy efficacy for microcystic lesions and refining surgical techniques to minimize complications.

Need Custom Synthesis?

Email: info@smolecule.com or [Request Quote Online](#).

References

1. Treatment of lymphangiomas by means of sclerotherapy with OK-432... [pmc.ncbi.nlm.nih.gov]
2. RBCP - Intralesional treatment of lymphatic malformations with... [rbcp.org.br]
3. Intra-abdominal cystic lymphangioma in adults: A case series of 32... [pmc.ncbi.nlm.nih.gov]
4. A novel surgical approach to treat lymphangioma of the breast and... [abs.amegroups.org]
5. Novel technique of sclerotherapy for superficial lymphatic ... [pmc.ncbi.nlm.nih.gov]
6. Case Report: Misdiagnosed cystic lymphangioma ... | F1000Research [f1000research.com]
7. Frontiers | Novel technique of sclerotherapy for superficial lymphatic... [frontiersin.org]

To cite this document: Smolecule. [Picibanil vs surgical excision lymphangioma]. Smolecule, [2026]. [Online PDF]. Available at: [<https://www.smolecule.com/products/b607217#picibanil-vs-surgical-excision-lymphangioma>]

Disclaimer & Data Validity:

The information provided in this document is for Research Use Only (RUO) and is strictly not intended for diagnostic or therapeutic procedures. While Smolecule strives to provide accurate protocols, we make no warranties, express or implied, regarding the fitness of this product for every specific experimental setup.

Technical Support: The protocols provided are for reference purposes. Unsure if this reagent suits your experiment? [Contact our Ph.D. Support Team for a compatibility check]

Need Industrial/Bulk Grade? Request Custom Synthesis Quote

Smolecule

Your Ultimate Destination for Small-Molecule (aka. smolecule) Compounds, Empowering Innovative Research Solutions Beyond Boundaries.

Contact

Address: Ontario, CA 91761, United States

Phone: (512) 262-9938

Email: info@smolecule.com

Web: www.smolecule.com