

Comprehensive Application Notes and Clinical Protocols: Picibanil Sclerotherapy for Ranula Management

Author: Smolecule Technical Support Team. **Date:** February 2026

Compound Focus: Picibanil

CAS No.: 39325-01-4

Cat. No.: S607217

[Get Quote](#)

Introduction and Disease Background

Ranula is a **mucous extravasation cyst** that forms in the floor of the mouth following the rupture or obstruction of salivary gland ducts, leading to the accumulation of saliva in surrounding tissues. The term "ranula" derives from the Latin word "rana" (frog), reflecting the translucent, bluish swelling that resembles a frog's underbelly [1]. Ranulas are classified into two distinct clinical variants: **simple ranulas**, which remain confined to the floor of the mouth above the mylohyoid muscle, and **plunging ranulas**, which extend through the mylohyoid muscle into the neck spaces [1] [2]. These lesions typically originate from the **sublingual salivary glands**, either from the greater sublingual gland (GSLG) in the posterior segment or the lesser sublingual glands (LSLG) and their associated Rivini ducts in the anterior segment [3] [4].

The **conventional management** of ranulas has primarily involved surgical interventions, including marsupialization (creating a permanent opening for drainage) or complete excision of the cyst along with the affected sublingual gland [5]. However, surgical approaches carry significant risks, including injury to **lingual nerves**, damage to **Wharton's duct** (which drains the submandibular gland), postoperative hematoma formation, and persistent recurrence with rates ranging from 25% to 89% depending on the surgical technique [5]. Additionally, surgical management often requires general anesthesia and involves substantial tissue dissection, leading to longer recovery times and increased healthcare costs. These

limitations have prompted the investigation of **minimally invasive alternatives**, particularly sclerotherapy, which has emerged as a promising treatment modality with favorable efficacy and safety profiles [6] [7].

Mechanism of Action

Picibanil (OK-432) is a **lyophilized biological preparation** derived from a low-virulence strain (Su) of Group A *Streptococcus pyogenes* that has been incubated with benzylpenicillin [7]. This sclerosing agent functions through a complex **immunomodulatory mechanism** that induces cyst resolution without the need for extensive surgical intervention. When injected into the cystic cavity, **Picibanil** initiates a **localized inflammatory cascade** characterized by the recruitment and activation of various immune cells, including neutrophils, macrophages, and T-lymphocytes [7]. These activated cells subsequently release a spectrum of **pro-inflammatory cytokines**, such as interleukin-6 (IL-6), tumor necrosis factor-alpha (TNF- α), and interferon-gamma (IFN- γ), which increase vascular permeability and initiate endothelial damage [7].

The **pathophysiological process** of cyst resolution involves multiple sequential phases. Initially, the cytokine-mediated inflammatory response damages the lymphatic endothelial cells lining the cyst wall, disrupting fluid transport mechanisms [7]. Subsequently, the increased vascular permeability leads to serum protein leakage and fibrin deposition within the cystic cavity, promoting **adhesion and collapse** of the cyst walls [8]. This inflammatory phase is followed by a **fibrotic stage** characterized by the activation of fibroblasts and deposition of collagen fibers, resulting in progressive shrinkage and eventual obliteration of the cystic space [7] [8]. The entire process typically occurs over **4-8 weeks**, with maximal therapeutic effect observed approximately 6 weeks post-procedure [7]. Unlike surgical excision, which physically removes the cyst but carries risks of nerve damage and recurrence, **Picibanil** sclerotherapy induces biological closure of the cyst while preserving surrounding anatomical structures and minimizing functional compromise.

Clinical Efficacy Data

Systematic Review Findings

The efficacy of **Picibanil** sclerotherapy for benign cystic lesions of the head and neck, including ranulas, has been evaluated in numerous clinical studies. A **comprehensive systematic review** published in 2021

analyzing 474 cases from 32 studies reported compelling outcomes across various cystic conditions [6]. The review demonstrated that **60.5%** of patients (287 cases) achieved **complete response** to sclerotherapy, while **27.9%** (132 cases) showed **partial response**, and only **11.6%** (55 cases) exhibited **no response** to treatment [6]. Importantly, the analysis revealed that **Picibanil demonstrated superior complete response rates** (62.0%) compared to ethanol (39.4%), with statistical significance ($p=0.015$) [6]. The overall requirement for subsequent surgical intervention following sclerotherapy was relatively low, occurring in only **11.2%** of cases (53 patients) across all sclerosing agents [6].

Agent-Specific Efficacy and Comparative Performance

Table 1: Comparative Efficacy of Sclerosing Agents for Ranula Treatment

Sclerosing Agent	Complete Response Rate	Partial Response Rate	No Response Rate	Key Advantages	Significant Limitations
Picibanil (OK-432)	62.0% [6]	27.9% (across all agents) [6]	11.6% (across all agents) [6]	Higher complete response rate; Favorable safety profile [6] [9]	Requires penicillin allergy testing; Inflammatory side effects [7] [8]
Ethanol	39.4% [6]	Similar partial response rate	Similar no response rate	Cost-effective; Potent sclerosing effect [7]	Higher risk of serious complications (nerve injury, skin necrosis) [7]
Bleomycin	65.0% (complete + general improvement) [4]	35.0% (general improvement) [4]	7.7% (5/65 cases) [4]	Effective for specific ranula types [4]	Potential pulmonary fibrosis; Limited to LSLG ranulas [7] [4]

Sclerosing Agent	Complete Response Rate	Partial Response Rate	No Response Rate	Key Advantages	Significant Limitations
Doxycycline	Not specifically reported for ranula	Not specifically reported for ranula	Not specifically reported for ranula	Widely available	Severe pain post-injection [7]

A **prospective observational study** specifically examining **Picibanil** sclerotherapy for cervical cysts demonstrated particularly promising results, with **nearly complete regression** observed in 8 of 14 patients (57.1%) and **complete regression** in 3 additional cases (21.4%) [9]. The remaining patients (21.4%) achieved significant cyst atrophy with only residual findings, and just one case required subsequent surgical excision [9]. These outcomes highlight the **potential of Picibanil** as a primary treatment modality that can potentially replace surgical extirpation in selected cases. The **therapeutic success** appears to be influenced by various factors, including cyst characteristics (unilocular versus multilocular), anatomical location, and previous interventions [7]. Specifically, unilocular cysts demonstrate better response rates compared to multilocular lesions, and macrocystic lymphatic malformations respond more favorably than microcystic variants [7].

Treatment Protocol

Patient Selection and Pre-procedural Evaluation

The **appropriate selection** of candidates for **Picibanil** sclerotherapy is crucial for achieving optimal therapeutic outcomes. Ideal candidates include patients with clinically diagnosed simple or plunging ranulas that are **symptomatic or causing functional impairment**, such as difficulties with speech, mastication, or swallowing [7] [1]. Prior to procedure initiation, a comprehensive **diagnostic workup** must be performed to confirm the benign nature of the lesion and exclude malignancy. This evaluation typically includes **clinical examination, ultrasonography** to characterize cyst architecture (unilocular vs. multilocular), and in complex cases, **MRI or CT imaging** to delineate the full extent of the lesion, particularly for plunging

ranulas [1] [2]. **Fine needle aspiration** (FNA) may be utilized to confirm the diagnosis by extracting cystic fluid for analysis [1].

A critical **pre-procedural consideration** involves conducting a **penicillin allergy assessment**, as **Picibanil** is derived from *Streptococcus pyogenes* incubated with benzylpenicillin [7] [8]. Patients with confirmed penicillin allergy should not receive **Picibanil**, and alternative sclerosing agents should be considered. Additional **contraindications** include the presence of active infection at the injection site, uncorrected coagulation disorders, and the inability to secure emergency airway management equipment in case of rare but potential laryngeal edema [6] [8]. For patients proceeding with **Picibanil** sclerotherapy, informed consent should specifically address the expected inflammatory response, potential need for multiple treatment sessions, and rare but serious complications.

Preparation and Administration Technique

Table 2: **Picibanil** Preparation and Dosing Protocol

Parameter	Specifications	Additional Considerations
Reconstitution	1 KE (Klinische Einheit) vial mixed with 10 mL normal saline [7]	Resulting concentration: 0.01 mg/mL [9]
Aspiration Volume	Aspirate entire cystic content before injection [7]	Record volume for appropriate dosing
Injection Volume	Equal to aspirated volume (maximum 20 mL regardless of aspirate) [7]	For multiloculated cysts: divide total volume among cavities
Procedure Setting	Outpatient clinic with ultrasound guidance [7]	Emergency airway equipment must be available
Repeat Injections	Assess response at 6-8 weeks; repeat if partial response [7]	Multiple sessions may be required for optimal effect

The **technical execution** of **Picibanil** sclerotherapy requires precision and adherence to established guidelines to maximize efficacy while minimizing complications. The procedure is typically performed

under **ultrasound guidance** to ensure accurate needle placement within the cystic cavity and to avoid surrounding vital structures [7]. After appropriate local anesthesia administration, the cystic fluid is completely aspirated, and the volume recorded. The prepared **Picibanil** solution (0.01 mg/mL) is then injected in a volume equivalent to the aspirated fluid, not exceeding the maximum recommended volume of 20 mL [7]. For **multiloculated cysts**, the total volume of sclerosing agent should be distributed among the individual cavities under ultrasound visualization. Following injection, patients are monitored for **acute adverse reactions** for approximately 2-4 hours before discharge, with specific instructions regarding expected post-procedural symptoms and emergency warning signs.

Post-procedural Care and Follow-up

The **post-sclerotherapy period** is characterized by a predictable **inflammatory response** that typically manifests as localized swelling, erythema, pain, and mild fever persisting for 3-5 days [7]. These symptoms represent expected therapeutic effects rather than complications and can be managed with **analgesics** (avoiding aspirin and NSAIDs in the immediate post-procedure period due to bleeding risk) and **antipyretics** [7]. Patients should be advised to maintain **adequate hydration** and consume a **soft diet** for several days to minimize discomfort during chewing and swallowing. Oral hygiene instructions should include **gentle cleansing** of the oral cavity without aggressive rinsing that might disrupt the injection site.

The **assessment of therapeutic response** should be conducted at approximately **6-8 weeks post-procedure**, as the maximal effect of **Picibanil** typically requires this duration for full manifestation [7]. Follow-up evaluation should include both **clinical examination** and **ultrasonographic imaging** to objectively measure cyst reduction [9]. For patients with **partial response** or residual cystic components, a second sclerotherapy session may be scheduled at this juncture. Successful treatment is defined as **complete clinical resolution** of the ranula with no ultrasonographic evidence of residual cyst, restoration of normal oral function, and absence of recurrence during long-term follow-up [6] [9]. Patients should be monitored periodically for **potential recurrence** for at least 6-12 months following successful treatment.

Safety and Adverse Events

Picibanil sclerotherapy demonstrates a **favorable safety profile** compared to surgical intervention and other sclerosing agents, particularly ethanol [6] [7]. The majority of adverse events associated with **Picibanil** are

mild to moderate in severity and directly related to the intended inflammatory mechanism of action. The most frequently reported side effects include **localized swelling** (approximately 40% of cases), **pain at the injection site** (25-35%), **transient fever** (18-20%), and **odynophagia** (difficulty swallowing, 16%) [7]. These symptoms typically emerge within 24-48 hours post-procedure and resolve spontaneously within 3-5 days with supportive care alone [7].

The systematic review of 474 cases documented only **one incident of laryngeal edema** requiring non-operative management, with no other major complications reported across the studied population [6]. However, the literature does document rare but **potentially serious adverse effects**, including a case of **severe inflammatory reaction** with extensive bleeding following peri-orbital injection [8] and an instance of **hyponatremia** secondary to syndrome of inappropriate antidiuretic hormone secretion (SIADH) following intrapleural administration [8]. Additionally, **hemolytic anemia** of presumed immune origin has been reported in one patient receiving **Picibanil** [8]. These serious complications, while rare, underscore the necessity of performing sclerotherapy in appropriately equipped facilities with personnel trained in emergency management.

When comparing the **safety profiles** of different sclerosing agents, ethanol demonstrates a notably higher incidence of **serious complications**, including nerve injury, skin necrosis, hemoglobinuria, and cardiovascular effects such as hypotension and even cardiopulmonary collapse in rare instances [7]. Bleomycin, while effective for some cystic conditions, carries the **potentially life-threatening risk** of pulmonary fibrosis, which limits its clinical utility [7] [3]. Doxycycline injections frequently cause **severe pain and discomfort** lasting 1-3 hours post-procedure [7]. In contrast, **Picibanil** offers a **superior therapeutic ratio** with comparable efficacy to these alternatives but with significantly fewer serious adverse events.

Comparative Treatment Analysis

Table 3: Comprehensive Comparison of Ranula Management Modalities

Treatment Modality	Efficacy (Cure Rate)	Recurrence Rate	Advantages	Disadvantages	Ideal Candidate
Picibanil Sclerotherapy	60.5% complete response; 27.9% partial response [6]	11.2% require surgery [6]	Minimally invasive; Low complication rate; No nerve injury risk [6] [9]	Inflammatory side effects; Multiple sessions possible [7]	Simple and plunging ranulas; Patients preferring non-surgical approach [6] [7]
Surgical Excision (Ranula + Gland)	98.8% cure rate [5]	0-2% [5]	Highest cure rate; Definitive treatment [5]	Nerve injury risk; Longer recovery; General anesthesia [5]	Large, recurrent, or plunging ranulas; Failed sclerotherapy [5]
Marsupialization with Packing	88-100% success [5]	0-12% [5]	Tissue preservation; Lower nerve injury risk	Packing discomfort; Longer healing; Multiple visits [5]	Simple ranulas; Pediatric patients [5]
Marsupialization Only	11-39% success [5]	61-89% [5]	Simple technique; Minimal tissue removal	High recurrence rate [5]	Temporary measure; Poor surgical candidates
Bleomycin Sclerotherapy	65% complete + 35% general improvement for LSLG ranulas [4]	0% for LSLG ranulas [4]	Effective for specific ranula types	Ineffective for GSLG ranulas; Pulmonary fibrosis risk [7] [4]	LSLG-derived ranulas only [4]

The **comparative analysis** of ranula management modalities reveals distinct **clinical applications** for each approach based on efficacy, safety, and practical considerations. **Surgical excision** of the ranula along with the sublingual gland remains the **gold standard** for definitive management, particularly for complex or recurrent cases, demonstrating the highest cure rate of 98.8% in meta-analyses [5]. However, this approach carries inherent risks of **nerve injury** (lingual and marginal mandibular), **duct damage**, and the need for **general anesthesia** with associated surgical risks [5]. **Marsupialization techniques** offer tissue-preserving alternatives with variable success rates—while simple marsupialization has unacceptably high recurrence rates (61-89%), the modified approach with prolonged packing demonstrates significantly better outcomes (0-12% recurrence) but requires patient tolerance of intraoral packing for 7-14 days [5].

Picibanil sclerotherapy occupies an important **therapeutic niche** as a minimally invasive primary intervention for both simple and plunging ranulas, offering a favorable balance of efficacy and safety [6] [9]. Its **unique advantages** include the ability to perform the procedure in an outpatient setting without general anesthesia, minimal tissue trauma, and negligible risk of nerve injury [6] [7]. The **principal limitations** include the predictable but uncomfortable inflammatory response and the potential need for multiple treatment sessions to achieve complete resolution [7]. **Bleomycin sclerotherapy** demonstrates remarkable efficacy (100% success) for ranulas originating from the lesser sublingual glands (LSLG) or Rivini ducts but shows no benefit for those derived from the greater sublingual gland (GSLG) [4]. This underscores the importance of **precise anatomical characterization** before selecting sclerotherapy agents.

Research Gaps and Future Directions

Despite the growing body of evidence supporting **Picibanil** sclerotherapy for ranula management, several **significant knowledge gaps** warrant further investigation. Well-designed **randomized controlled trials** directly comparing **Picibanil** sclerotherapy with surgical excision (the current gold standard) are notably lacking in the literature [6] [5]. Such studies should employ **standardized outcome measures**, including patient-reported quality of life metrics, functional assessments, and comprehensive economic analyses to fully evaluate the comparative effectiveness of these approaches. Additionally, research focusing on **predictive factors** for treatment success remains limited, with insufficient evidence regarding how cyst characteristics (size, loculation, anatomical origin), patient factors (age, previous treatments), and technical considerations (injection volume, concentration, ultrasound guidance techniques) influence therapeutic outcomes [6] [7].

Future research directions should prioritize several key areas. **Combination approaches** utilizing **Picibanil** with other treatment modalities represent a promising avenue for investigation, particularly for complex or multiloculated cysts that demonstrate suboptimal response to single-modality therapy [7]. The development of **novel sclerosing agents** with improved efficacy and reduced inflammatory side effects would address significant limitations of current options [7]. Furthermore, **long-term outcome studies** with extended follow-up periods (5-10 years) are essential to definitively establish the durability of **Picibanil** sclerotherapy and its true recurrence rates compared to surgical management [6] [9]. Technical refinements in **image-guided injection techniques**, including the use of contrast-enhanced ultrasound and real-time monitoring of sclerosant distribution, may enhance precision and treatment outcomes while minimizing complications [7]. Finally, **patient selection algorithms** incorporating imaging characteristics, clinical presentation, and molecular markers would enable more personalized treatment approaches and optimize resource utilization.

Conclusions and Recommendations

Picibanil sclerotherapy represents a **highly valuable therapeutic option** in the comprehensive management of ranulas, demonstrating a favorable balance of efficacy and safety based on current evidence. The procedure offers distinct advantages as a **minimally invasive alternative** to surgical excision, particularly for patients who are suboptimal surgical candidates, those wishing to avoid general anesthesia, or individuals concerned about the risk of nerve injury associated with surgical dissection [6] [7] [9]. The **clinical application** of **Picibanil** should be guided by careful patient selection, thorough pre-procedural evaluation to exclude malignancy and confirm benign cystic pathology, and appropriate technical execution with ultrasound guidance to ensure precise intracystic injection [7] [9].

Based on the available evidence, the following **evidence-based recommendations** are proposed:

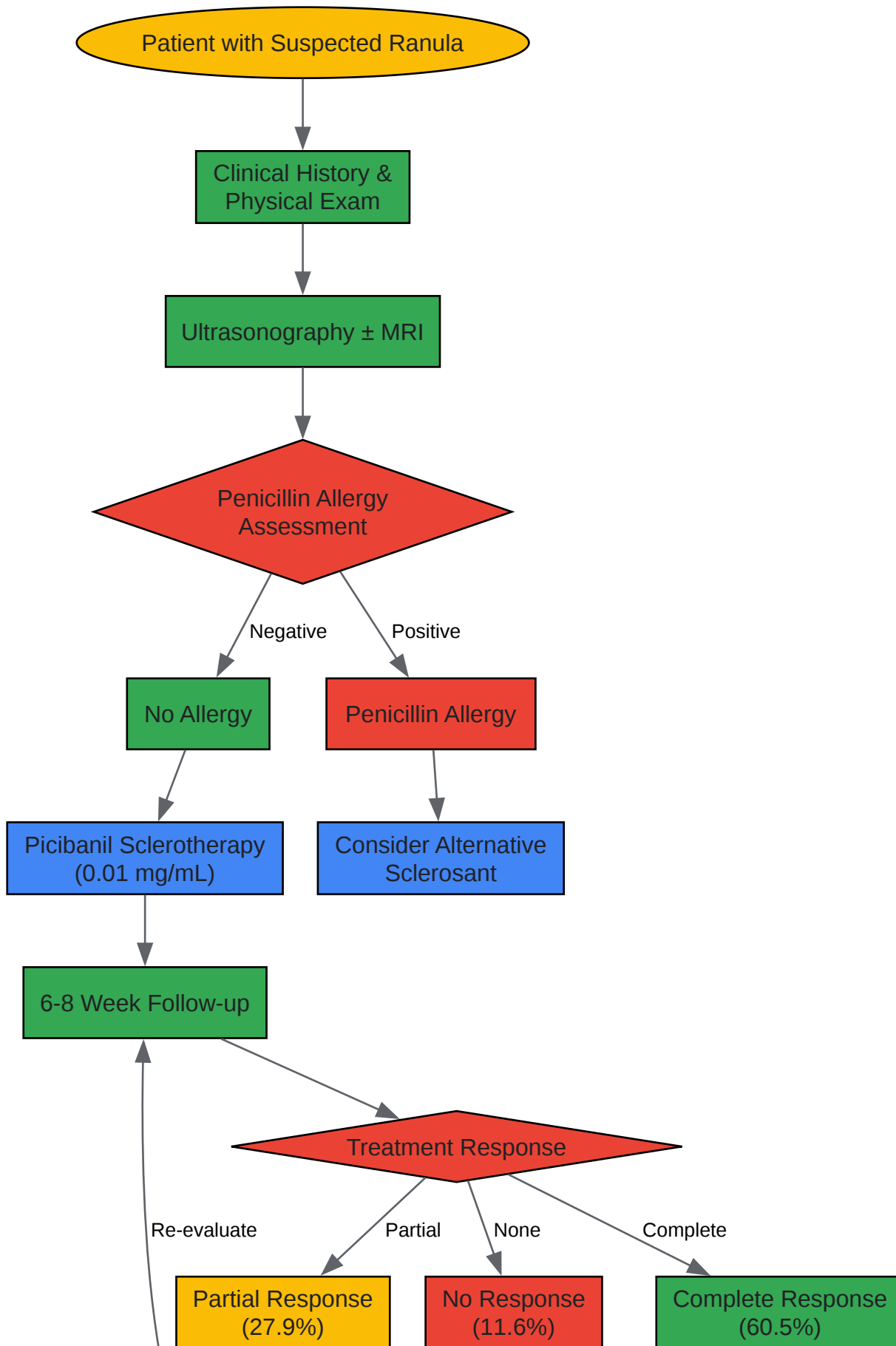
- **First-line consideration:** **Picibanil** sclerotherapy should be considered as a primary treatment option for both simple and plunging ranulas, particularly those that are unilocular and of moderate size [6] [7].
- **Pre-procedural requirements:** Comprehensive imaging (ultrasonography ± MRI) and penicillin allergy testing are mandatory before treatment initiation [7] [1].
- **Technical execution:** Procedures should be performed under ultrasound guidance with appropriate dosing (0.01 mg/mL concentration, volume matching aspirated fluid, maximum 20 mL) [7] [9].

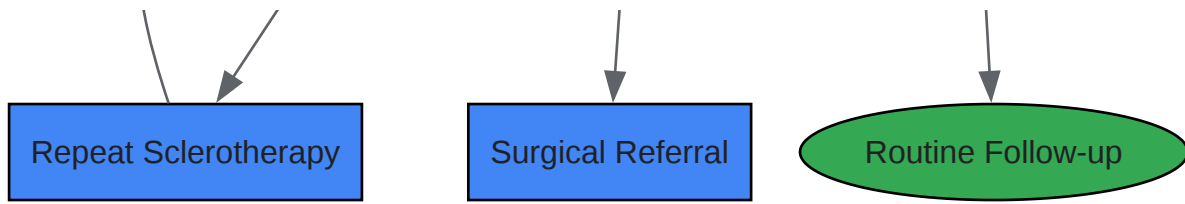
- **Post-procedural management:** Patients should be educated about the expected inflammatory response and monitored for 6-8 weeks before assessing need for additional sessions [7].
- **Surgical consultation:** Cases with inadequate response after 2-3 sclerotherapy sessions or with features suggesting complex anatomy should be referred for surgical evaluation [6] [5].

The integration of **Picibanil** sclerotherapy into clinical practice requires a **multidisciplinary approach** involving otolaryngologists, oral surgeons, interventional radiologists, and pathologists to optimize patient selection, technical performance, and outcomes assessment. Future research efforts should focus on addressing current knowledge gaps through rigorous comparative effectiveness studies and long-term outcome assessments to further refine the role of this promising minimally invasive therapy in ranula management.

Diagrams

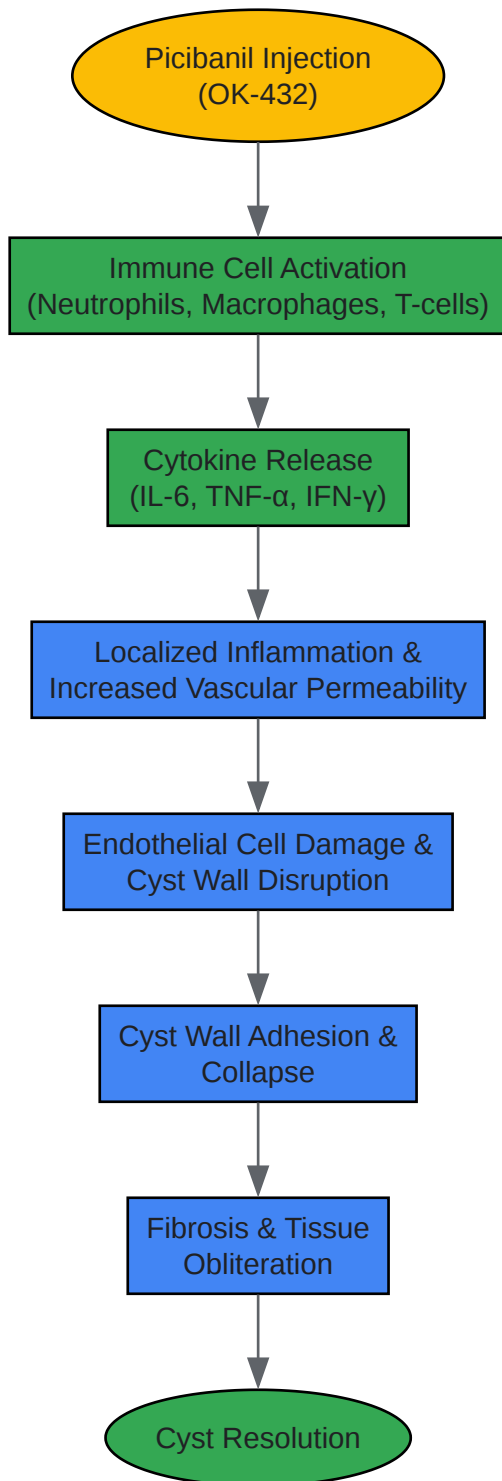
Figure 1: Picibanil Sclerotherapy Clinical Decision Pathway





[Click to download full resolution via product page](#)

Figure 2: Picibanil Mechanism of Action - Immunological Pathway



Click to download full resolution via product page

Need Custom Synthesis?

Email: info@smolecule.com or Request Quote Online.

References

1. : Types, Causes, Symptoms, Diagnosis and Ranula Treatment [medicoverhospitals.in]
2. - Causes, Symptoms, Diagnosis, and Ranula Treatment [apollohospitals.com]
3. for the intraoral Sclerotherapy with bleomycin: technical... ranula [pmc.ncbi.nlm.nih.gov]
4. for the intraoral Sclerotherapy with bleomycin: technical... ranula [bmcoralhealth.biomedcentral.com]
5. Mucocele and Ranula Treatment & Management: Medical Care... [emedicine.medscape.com]
6. for Benign Cystic Lesions of the Head and Neck... Sclerotherapy [pubmed.ncbi.nlm.nih.gov]
7. Ultrasound-guided sclerotherapy for benign non-thyroid cystic mass in... [pmc.ncbi.nlm.nih.gov]
8. sciencedirect.com/topics/pharmacology-toxicology-and-pharmaceutical... [sciencedirect.com]
9. of cervical cysts with Sclerotherapy (OK-432) Picibanil [link.springer.com]

To cite this document: Smolecule. [Comprehensive Application Notes and Clinical Protocols: Picibanil Sclerotherapy for Ranula Management]. Smolecule, [2026]. [Online PDF]. Available at: [https://www.smolecule.com/products/b607217#picibanil-sclerotherapy-for-ranula]

Disclaimer & Data Validity:

The information provided in this document is for Research Use Only (RUO) and is strictly not intended for diagnostic or therapeutic procedures. While Smolecule strives to provide accurate protocols, we make no warranties, express or implied, regarding the fitness of this product for every specific experimental setup.

Technical Support: The protocols provided are for reference purposes. Unsure if this reagent suits your experiment? [Contact our Ph.D. Support Team for a compatibility check]

Need Industrial/Bulk Grade? Request Custom Synthesis Quote

Smolecule

Your Ultimate Destination for Small-Molecule (aka. smolecule) Compounds, Empowering Innovative Research Solutions Beyond Boundaries.

Contact

Address: Ontario, CA 91761, United States

Phone: (512) 262-9938

Email: info@smolecule.com

Web: www.smolecule.com