

# Airway Obstruction Risk in OK-432 Sclerotherapy

Author: Smolecule Technical Support Team. Date: February 2026

## Compound Focus: Picibanil

CAS No.: 39325-01-4

Cat. No.: S607217

[Get Quote](#)

Risk Factor	Reported Cases & Context	Onset & Key Clinical Signs	Recommended Preventive Measures
<b>Transient inflammatory swelling</b> post-injection [1] [2]	Case: 5-month-old with <b>cervical lymphangioma</b> ; required emergency intubation after infection-induced enlargement [1].	<b>Rapid progression</b> (within immediate postoperative period); stridor, respiratory distress, declined oxygen saturation [1] [2].	<b>Prophylactic elective tracheostomy</b> for lesions with tracheal compression, if reintubation is anticipated to be difficult [1].
<b>Lesion location</b> in head, neck, tongue, or airway [1] [3] [2]	Case: 5-year-old with <b>lingual lymphangioma</b> ; required emergency fiberoptic intubation post-injection [2].	Severe diffuse swelling, progressive upper airway obstruction, inspiratory stridor [2].	<b>Airway endoscopy</b> to assess submucosal extension and infiltration of pharyngeal mucosa [3].
<b>Underlying infection</b> in the lymphangioma [1]	Case: 2-month-old with pharyngeal infiltration; <b>tracheostomy performed pre-sclerotherapy</b> to secure airway [3].	Fever can be a trigger; worsening stridor and respiratory effort [1] [3].	<b>Prophylactic antibiotics</b> to manage infection risk, especially with necrotic tissue [4].

## Detailed Experimental & Clinical Protocols

### Patient Selection and Pre-Procedure Workup

A thorough pre-procedure assessment is critical for identifying high-risk patients.

- **Imaging Diagnosis:** Confirm the lymphangioma using **cervical MRI** to define the size, extent, and relationship to critical structures. MRI effectively shows multiloculated lesions in the retropharyngeal and parapharyngeal spaces [3].
- **Airway Endoscopy:** Perform an **airway endoscopy under general anesthesia** to visually identify any submucosal extension of the lymphangioma into the pharynx (from nasopharynx to hypopharynx) that could cause intrinsic airway obstruction [3].
- **Risk Stratification:** Classify the lymphangioma. Be aware that **microcystic** and **suprahyoid** lesions are more challenging to treat and may pose a higher risk [3].

### Emergency Airway Management Protocol

Given the potential for rapid obstruction, a clear emergency protocol is essential.

- **Immediate Intervention:** Respiratory distress can progress rapidly. Prepare for **emergency tracheal intubation**. In cases of upper airway obstruction, avoid muscle relaxants during induction for anesthesia [1].
- **Prophylactic Securing of the Airway:** For patients with significant tracheal compression where post-operative swelling is anticipated, **prophylactic and elective tracheostomy** should be considered *before* sclerotherapy. This provides a secure airway during the period of transient swelling following OK-432 injection and avoids the difficulty of emergency reintubation [1] [3].
- **Post-Injection Monitoring:** Closely monitor the patient for **fever, local pain, and edema** in the hours and days following the injection. These are common inflammatory responses to OK-432 and can be managed with antipyretics, but they also signal the need for heightened airway vigilance [3].

### Mechanism of Action and Complication Pathway

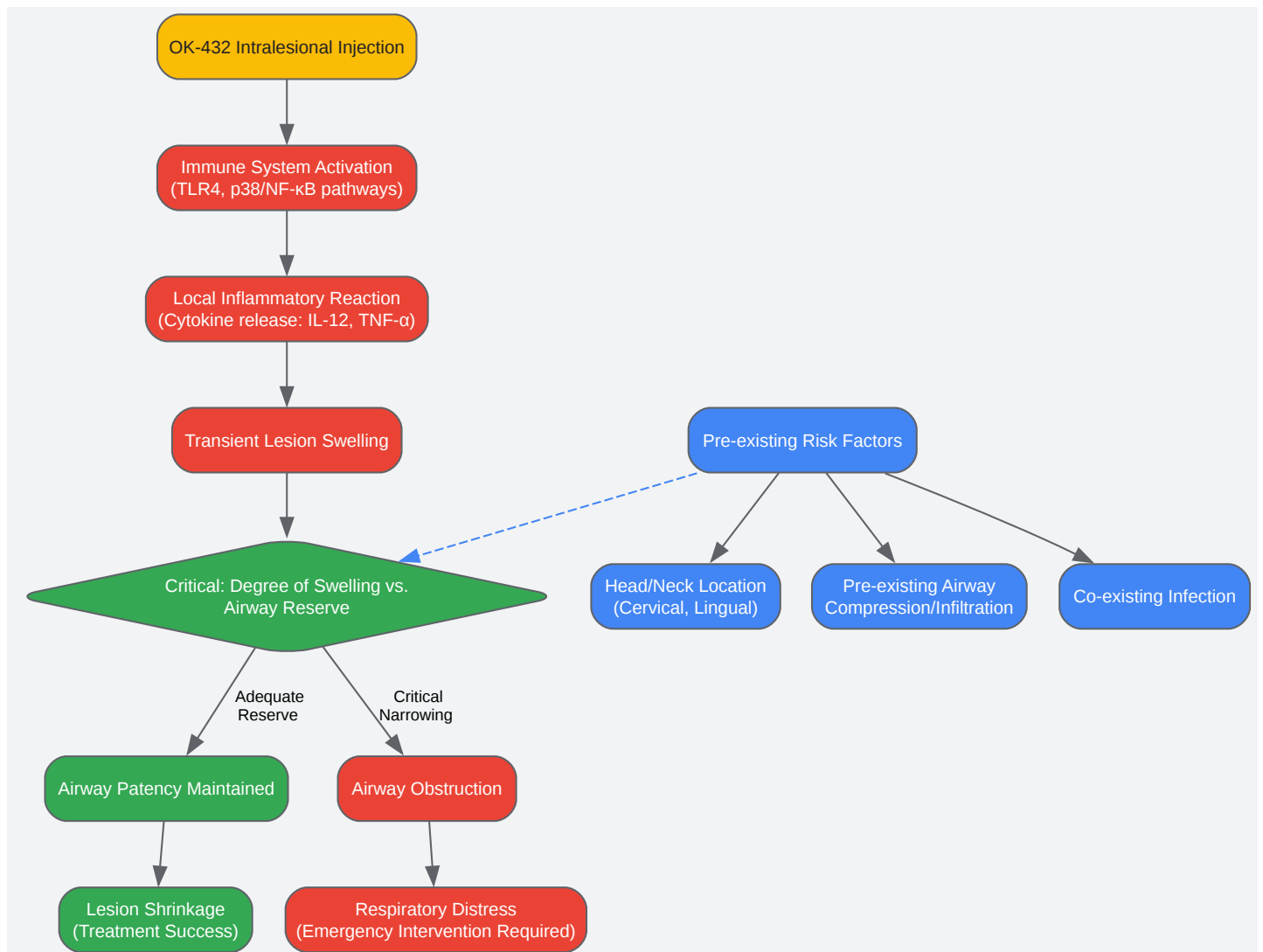
Understanding the biological mechanism of OK-432 explains the side effect of swelling.

- **Immune Activation:** OK-432 is a streptococcal preparation that acts as an immunostimulant. It induces a local inflammatory reaction, activating immune pathways like **p38** and **NF-κB** in antigen-

presenting cells, leading to the secretion of cytokines like **TNF- $\alpha$**  and **IL-12** [5] [6].

- **Desired vs. Adverse Effect:** This inflammatory response is intended to cause sclerosis and eventual shrinkage of the lymphangioma. However, the initial effect is **transient edema** due to the inflammation, which can critically compromise a narrowed airway [1] [2].

The diagram below illustrates the pathway from OK-432 injection to potential airway complication, highlighting the key mechanisms and decision points.



Click to download full resolution via product page

## Frequently Asked Questions (FAQs)

- **Q1: What is the most significant risk factor for airway obstruction during OK-432 sclerotherapy?** The primary risk factor is the **location of the lesion**. Lesions in the head and neck region, particularly those that are cervical, lingual, or have submucosal extension into the pharynx, pose the highest risk. The transient swelling caused by the drug's inflammatory action can critically narrow an already compromised airway [1] [3] [2].
- **Q2: What pre-clinical models can be used to study this risk?** While the search results did not specify pre-clinical models for airway risk, they indicate that **mouse models** (e.g., BALB/c with 4T1 breast cancer cells) and **rabbit models** (e.g., with VX2 tumors) are well-established for studying the immune effects and efficacy of OK-432 in an oncological context [7] [8]. Research into the inflammatory pathways (p38/NF-κB) activated by OK-432 can be conducted *in vitro* using human monocyte-derived dendritic cells [5] [9].
- **Q3: Are there any systemic risks besides airway obstruction?** Yes, although rare, high-dose administration of OK-432, particularly in patients with advanced cancer, has been associated with severe systemic complications, including **circulatory shock and disseminated intravascular coagulation (DIC)**. These events are thought to be potentially related to gram-negative bacteremia secondary to the drug's effect [4].

### Need Custom Synthesis?

Email: [info@smolecule.com](mailto:info@smolecule.com) or Request Quote Online.

## References

1. caused by rapid enlargement of cervical... Airway obstruction [pmc.ncbi.nlm.nih.gov]
2. [Severe iatrogenic airway due to lingual lymphangioma] obstruction [pubmed.ncbi.nlm.nih.gov]

3. Response to OK - 432 sclerotherapy in the treatment of cervical... [bjorl.org]
4. [ Complications due to high-dose OK - 432 administration into tumors...] [pubmed.ncbi.nlm.nih.gov]
5. The pivotal role of p38 and NF-kappaB signal in the... pathways [pubmed.ncbi.nlm.nih.gov]
6. Streptococcal preparation OK - 432 is a potent inducer of IL-12 and... [pubmed.ncbi.nlm.nih.gov]
7. Microwave ablation combined with OK - 432 induces Th1-type response... [translational-medicine.biomedcentral.com]
8. Radiofrequency Ablation of Liver Tumors in Combination with Local... [link.springer.com]
9. Interferon- $\alpha$ -inducible Dendritic Cells Matured with OK - 432 Exhibit... [nature.com]

To cite this document: Smolecule. [Airway Obstruction Risk in OK-432 Sclerotherapy]. Smolecule, [2026]. [Online PDF]. Available at: [<https://www.smolecule.com/products/b607217#ok-432-complications-airway-obstruction-risk>]

---

#### Disclaimer & Data Validity:

The information provided in this document is for Research Use Only (RUO) and is strictly not intended for diagnostic or therapeutic procedures. While Smolecule strives to provide accurate protocols, we make no warranties, express or implied, regarding the fitness of this product for every specific experimental setup.

**Technical Support:** The protocols provided are for reference purposes. Unsure if this reagent suits your experiment? [Contact our Ph.D. Support Team for a compatibility check]

**Need Industrial/Bulk Grade?** Request Custom Synthesis Quote

## Smolecule

Your Ultimate Destination for Small-Molecule (aka. smolecule) Compounds, Empowering Innovative Research Solutions Beyond Boundaries.

### Contact

**Address:** Ontario, CA 91761, United States

**Phone:** (512) 262-9938

**Email:** [info@smolecule.com](mailto:info@smolecule.com)

**Web:** [www.smolecule.com](http://www.smolecule.com)