

Cobimetinib serous retinopathy visual disturbances

Author: Smolecule Technical Support Team. **Date:** February 2026

Compound Focus: Cobimetinib

CAS No.: 934660-93-2

Cat. No.: S548756

[Get Quote](#)

Clinical Characteristics & Quantitative Profile

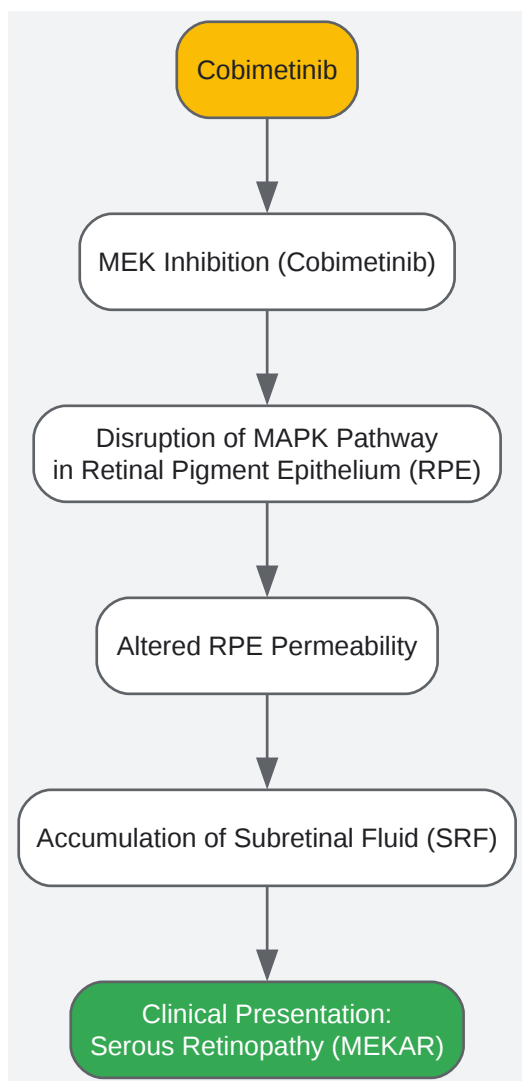
The table below summarizes the core quantitative data on **Cobimetinib**-associated serous retinopathy (also referred to as MEK inhibitor-associated retinopathy or MEKAR) from integrated clinical analyses [1] [2].

Parameter	Summary Data
Incidence	17.9% - 26% in patients receiving Cobimetinib combination therapy [1] [2]
Recurrence Rate	3.7% had ≥ 2 events; 0.6% had ≥ 3 events [1]
Severity (Grade 3/4)	<2.5% - 11% (Grade 3-4 events) [1] [2]
Time to Onset (Median)	15 days - 1.0 month [1] [2]
Time to Resolution (Median)	26 days [1]
Presentation	Bilateral, focal (62.8%) or multifocal (25.7%) subretinal fluid (SRF) [1]
Impact on Visual Acuity	Typically asymptomatic or mild symptoms; no permanent visual loss or retinal damage identified [1]

Pathophysiology & Mechanism of Action

The ocular toxicity is an "on-target, off-tumor" effect. The MAPK signaling pathway, which **Cobimetinib** inhibits, plays a critical role in maintaining the health and function of the retinal pigment epithelium (RPE) [1]. Inhibition of MEK1/2 is thought to alter the permeability of the RPE, disrupting fluid transport and leading to the accumulation of **subretinal fluid (SRF)** and retinal pigment epithelial detachments (RPEDs) [1]. This mechanism is distinct from classic central serous chorioretinopathy, as **Cobimetinib**-associated SRF is not linked to vascular leakage on angiography [2].

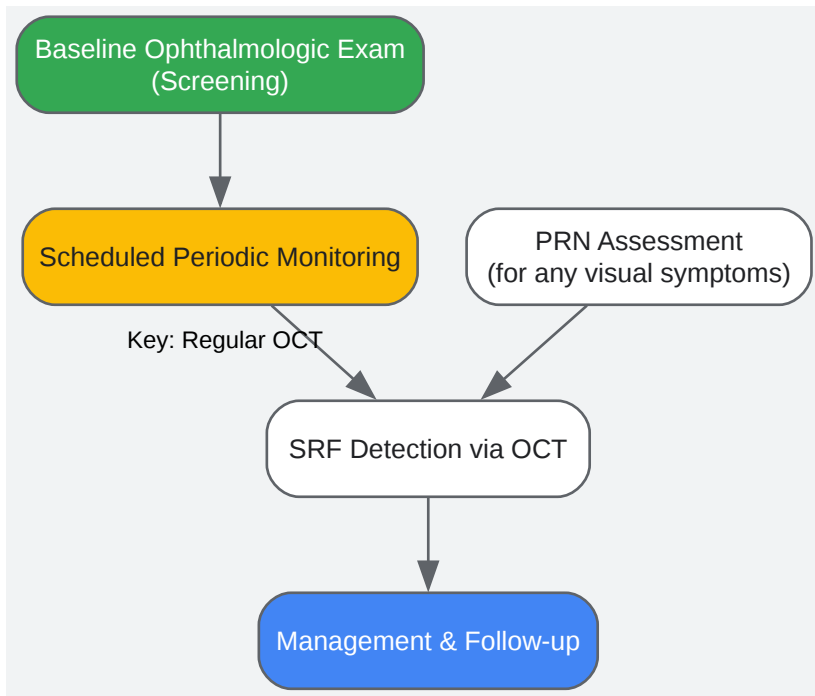
This mechanism can be visualized in the following pathway diagram:



[Click to download full resolution via product page](#)

Diagnostic & Monitoring Protocols

A key learning from clinical trials is that a significant proportion of serous retinopathy cases are **asymptomatic** and are only detected through systematic ophthalmic screening [2]. The following workflow outlines a standardized monitoring approach, synthesized from study protocols [1].



[Click to download full resolution via product page](#)

Detailed Methodologies for Key Assessments:

- **Optical Coherence Tomography (OCT):** This is the **gold-standard** imaging modality for detecting and characterizing MEKAR [3]. It identifies SRF accumulations, which often present as bilateral, multifocal, dome-shaped elevations of the neurosensory retina [4]. These are described as "MEKAR lesions" [4].
- **Comprehensive Ophthalmic Examination:** As implemented in studies like CO39721, this should include [1]:
 - **Best-Corrected Visual Acuity (BCVA) Testing:** To quantitatively assess visual function.
 - **Slit-Lamp Biomicroscopy:** For anterior segment evaluation.
 - **Indirect Ophthalmoscopy:** For a wide-field view of the retina.
 - **Intraocular Pressure Measurement.**

Management & Troubleshooting Guide for Researchers

The following table translates clinical management strategies into a troubleshooting guide for protocol development.

Scenario / 'Bug'	Recommended 'Fix' (Clinical Management)	Evidence & Rationale
Asymptomatic / Grade 1 SRF	Observation without dose modification. Continue Cobimetinib and monitoring.	~48% of patients recovered without any dose change [1]. The condition is often self-limiting [5].
Mildly Symptomatic SRF	Consider temporary dose interruption until symptoms resolve to Grade ≤ 1 , then resume at the same or reduced dose.	~16% of patients recovered after a dose modification [1]. Most events resolved with or without intervention [2].
Recurrent or Grade ≥ 3 SRF	Dose reduction or permanent discontinuation of Cobimetinib.	Protocol-mandated for severe or recurrent cases [2]. Permanent vision loss is rare, but symptom severity may warrant therapy alteration [1] [2].
Concomitant Uveitis	Manage with topical corticosteroids (e.g., dexamethasone). Cobimetinib may be continued.	Uveitis is more commonly associated with BRAF inhibitors [5]. A case report showed resolution of uveitis and cystoid macular edema with topical steroids while continuing combo therapy [4].

Frequently Asked Questions for Protocol Design

Q1: How do we distinguish MEKAR from classic Central Serous Chorioretinopathy (CSCR)? **A:** MEKAR is typically **bilateral**, with **multiple foci** of SRF, and occurs soon after drug initiation. In contrast, classic CSCR is often unilateral, with a single leak point, and is associated with steroid use or stress. Crucially, fluorescein angiography in MEKAR shows **no active leakage**, distinguishing it from CSCR [2].

Q2: Are there specific patient exclusion criteria to mitigate risk in clinical trials? **A:** Yes, common exclusion criteria in **Cobimetinib** trials include a history of retinal pathology considered a risk factor for central serous chorioretinopathy, retinal vein occlusion (RVO), or neovascular macular degeneration [1] [2].

Q3: Is the retinopathy reversible upon drug discontinuation? **A:** Yes, the evidence consistently indicates that **Cobimetinib**-associated serous retinopathy is reversible. Comprehensive ophthalmologic assessments have not identified permanent retinal damage, and fluid resolves upon dose modification or cessation [1] [3].

Q4: How should monitoring protocols be designed for asymptomatic patients? **A:** Proactive, scheduled monitoring is essential. A proposed schedule includes examinations at screening, every 2 weeks for the first 1-2 cycles, then monthly for the next few cycles, and every 3 cycles thereafter, with additional assessments for any new visual symptoms [1].

Need Custom Synthesis?

Email: info@smolecule.com or [Request Quote Online](#).

References

1. Characterization of Serous Retinopathy Associated with ... [pmc.ncbi.nlm.nih.gov]
2. Clinical features of serous retinopathy observed with ... [translational-medicine.biomedcentral.com]
3. Managing Retinal Toxicity From Systemic Medications [eyesoneyecare.com]
4. Ocular Changes in Metastatic Melanoma Patients Treated with ... [pmc.ncbi.nlm.nih.gov]
5. Systemic Chemotherapy and Ocular Toxicities [eyewiki.org]

To cite this document: Smolecule. [Cobimetinib serous retinopathy visual disturbances]. Smolecule, [2026]. [Online PDF]. Available at: [<https://www.smolecule.com/products/b548756#cobimetinib-serous-retinopathy-visual-disturbances>]

Disclaimer & Data Validity:

The information provided in this document is for Research Use Only (RUO) and is strictly not intended for diagnostic or therapeutic procedures. While Smolecule strives to provide accurate protocols, we make no warranties, express or implied, regarding the fitness of this product for every specific experimental setup.

Technical Support: The protocols provided are for reference purposes. Unsure if this reagent suits your experiment? [Contact our Ph.D. Support Team for a compatibility check]

Need Industrial/Bulk Grade? Request Custom Synthesis Quote

Smolecule

Your Ultimate Destination for Small-Molecule (aka. smolecule) Compounds, Empowering Innovative Research Solutions Beyond Boundaries.

Contact

Address: Ontario, CA 91761, United States

Phone: (512) 262-9938

Email: info@smolecule.com

Web: www.smolecule.com